

1. Introduction

a. The word “laser” is an acronym for “light amplification by stimulated emission of radiation.” In common usage, a laser is a device that produces an intense, narrow beam of light. Normally each laser can only produce a single frequency or color of radiation. However, there are many different types of lasers. Some produce light which is in the visible portion of the radiation spectrum and, therefore, can be seen. Others produce radiation which is outside of the visible spectrum (either infrared or ultraviolet) and is, therefore, invisible. Appendix A depicts the wavelength of common lasers. Some laser devices produce radiation with sufficient energy to severely injure or burn the eyes or skin of personnel who are down range. The use of laser devices, such as rangefinders and target designators may result in accidental injury to the eye. Appendix A also depicts some of the lasers commonly found in the United States Army. It is possible that similar devices may be used by opposing forces as antipersonnel weapons.

b. The beam of light emitted from a laser device is normally very narrow, usually less than an inch in diameter. However, over long distances, the beam progressively becomes wider. For a military laser, the beam is typically 1 meter in diameter at a distance of 1 kilometer and 2 meters in diameter at a distance of 2 kilometers. Thus, a laser can irradiate the whole body at these distances. If the energy of the laser is high enough, such exposures could burn clothing, skin, or any part of the body exposed to the beam. Most lasers, however, are not powerful enough to generate burns. Because the eye focuses and concentrates whatever light that enters the eye, it is extremely sensitive to injury from almost any type of laser device. The concentration of energy which is focused onto the back of the eye can be 100,000 times greater than the energy which enters at the front of the eye. Thus depending upon the type of laser, the energy output of the laser, and the distance from the laser, a spectrum of injuries can be expected. These may range from very tiny lesions in the back of the eye to severe burns affecting vast portions of the body. See Appendix A for principal wavelengths of common lasers.

c. Injuries to the eye result when the energy from the laser is absorbed by various anatomical structures. The frequency of the laser radiation determines which structure absorbs the energy (Figure 1).

(1) *Ultraviolet*. Lasers operating in the ultraviolet spectrum (below 400 nm UV-A,B,C) are absorbed in the anterior segments of the eye, primarily by the cornea, as well as by the lens.

(2) *Visible*. Laser radiations in the visible spectrum (400-700 nm) are absorbed primarily within the retina by the pigment epitheliums and the choroid.

(3) *Infrared*. Absorption of lasers in the infrared spectrum occurs in two areas of the eye. Lasers at the near-infrared spectrum (700-1400 nm IR-A) damage the retina and the choroid, whereas light in the far-infrared spectrum (above 1400 nm IR-B,C) damages the cornea.

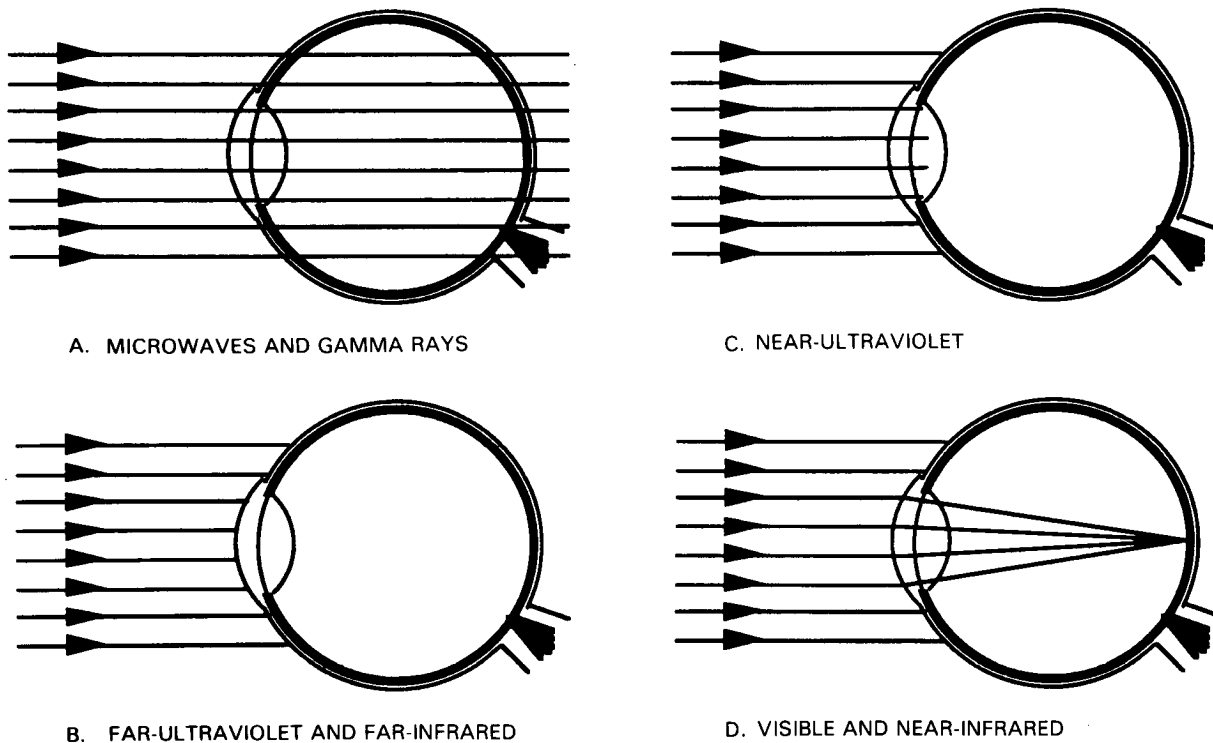


Figure 1. Schematic diagram of the absorption of electromagnetic radiation in the eye.

2. Threat

a. Potential Employment. The rapid growth of laser science has resulted in an increased use of laser instruments in the military. Currently lasers exist on the battlefields as rangefinders and target designators. They are also used to simulate live fire during force-on-force exercises. We have devices which can accidentally permanently blind us; therefore, it is likely that threat forces have similar equipment. This may increase the potential for laser eye injuries on the battlefield. In the future lasers may be used as antipersonnel devices/weapons to disrupt military performance by reducing the soldiers' ability to see.

b. Laser Effects on Visual Performance. Lasers may interfere with vision either temporarily or permanently in one or both eyes. At low energy levels, lasers may produce temporary reduction in visual performance in critical military tasks, such as aiming weapons or flying aircraft. At higher energy levels they may produce serious long-term visual loss, even permanent blindness. Critical military functions, such as reading a map or driving, may be impossible. Furthermore, soldiers who sustain minimal injuries or even no injury from low-energy laser exposures may develop serious psychological problems and become ineffective in the performance of their duties. Such psychological reactions may also develop among other soldiers assigned to units in which laser injuries have been reported. Such reactions could affect morale and discipline, as well as the overall ability of the unit to accomplish its assigned mission.

3. Anatomy of the Eye

From the laser effects viewpoint, the eye is composed of four systems (Figure 2).

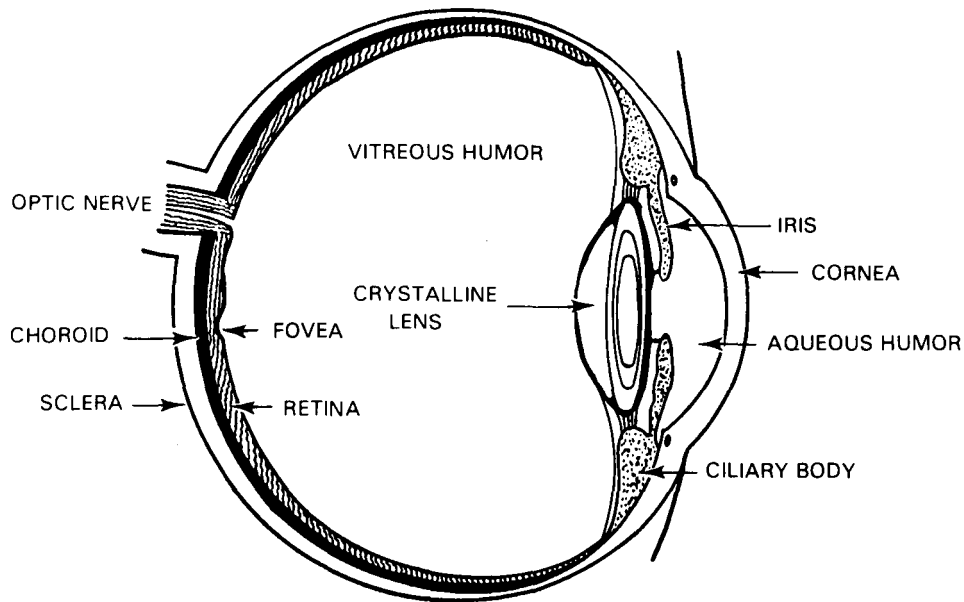


Figure 2. Anatomy of the eye.

a. Light Transmission and Focusing System.

(1) *Cornea* The transparent front part of the eye which separates it from the air. The cornea is continuous with the sclera (white of the eye). The cornea transmits most laser wavelengths except for ultraviolet and far-infrared irradiation which at high energies may burn it.

(2) *Iris*. The colored diaphragm with an aperture (pupil) in its center. The iris controls the amount of light entering the eye by widening (dilating) the pupil at twilight, night, and dawn; narrowing (constricting) the pupil at daylight. Therefore, most lasers are much more dangerous under low light conditions; more light enters the eye through the wide pupil hitting the retina.

(3) *Lens*. A transparent structure located immediately behind the pupil which focuses light on the retina. Visible and near-infrared light pass through the lens, but near-ultraviolet light is absorbed by it.

(4) *Vitreous humor.* The jelly-like substance which fills the area of the eye between the lens and the retina. It is transparent to both visible and near-infrared radiation. The vitreous humor also serves as a structural support for the retina.

b. The Light Absorption and Transduction System. The retina comprises this system which lines the inside of the eyeball. The retina consists primarily of photoreceptor and nerve cells. The layer of nerve cells lies on top of the photoreceptor cells but is transparent, so light entering through the pupil actually passes through the nerve cell layer before reaching the photoreceptor cells. The photoreceptor cells convert the energy of absorbed light into nerve impulses. These impulses are received by the nerve cells which transmit them to the brain through the optic nerve which exits the back of the eye. The retina is particularly sensitive to laser irradiation since the laser beam is well focused on it. EXAMPLE: All the light entering a 5mm pupil is concentrated to a 0.050mm or smaller in diameter area on the retina, multiplying the energy density 10,000 times or more. If the beam enters the eye through binoculars or other magnifying optics, it is even more dangerous since the energy concentration increases up to a million times. The retina has the following two parts (Figure 2).

(1) *Fovea.* The central 1.5mm at the back of the eye. The fovea is the only part of the eye in which precise vision takes place enabling location of small and distant targets, and detection of colors. If the fovea is damaged, the person is blinded; he can hardly see the top figure on the eye chart and cannot see colors. The fovea and fine visual function can also be affected by retinal injuries occurring at some distance from the fovea. Many injuries, especially those caused by lasers, are surrounded by a zone of inflammation and swelling which, when it extends into the region of the fovea, can reduce foveal function. The actual degree of visual impairment will depend upon the location and extent of both injury and the inflammatory response. In general, the closer the injury is to the fovea, the greater the chance of severe dysfunction.

(2) *Retinal periphery.* The retinal periphery is all of the retinal area surrounding the fovea and is involved in a variety of functions. Because it has a high concentration of photoreceptor cells which operate during dim or dark conditions, one of its primary functions is night vision. During bright conditions the peripheral retina detects motion (peripheral vision). Unlike the fovea, however, the peripheral retina is unable to detect small or distant objects or to distinguish between fine shades of color. A laser injury restricted to this portion of the retina will have a minimal effect on normal visual function. Soldiers with isolated laser injuries in the retinal periphery may report having been dazzled at the time of exposure and may detect a dark spot (scotoma) in their peripheral vision; they should be able to perform all fine visual tasks normally. After a period of time the soldier will adapt to the presence of small- to medium-sized scotomas, even though the retina may be permanently damaged; he will eventually become unaware of it. Laser injuries which involve large portions of the peripheral retina may cause large defects in the individual's peripheral vision; he may always be aware of these.

c. The Maintenance System. This system consists primarily of the choroid, a rich network of blood vessels on and behind the retina. When this network is injured by a laser beam, it bleeds and may lead to partial or complete, temporary or permanent blindness.

d. The Support System. The eyelids are the most relevant parts of this system; they may limit the laser injury to 0.15 seconds, the duration of the blink reflex. The eyelids themselves may be burned by high energy infrared laser irradiation together with surrounding skin and the cornea.

4. Prevention/Protection

a. Laser protective eyewear will prevent ocular injury from laser radiation emitted by low energy laser rangefinders and target designators. The recently developed and fielded ballistic and laser protective eyewear (B-LPS) will protect the eye against ballistic fragments and specified fixed wavelength laser hazards. Narrow band filter eyewear made of polycarbonate ballistic-fragment-resistive material will reject specific laser wavelengths while transmitting light required for vision (Figure 3). The tint or color associated with laser protective eyewear may degrade vision and military performance under low light conditions; that is, dawn, dusk, or night. Current protective eyewear is designed to protect against specific laser hazards; therefore, the use of issued protective eyewear does not preclude injury to the eye from other threat laser wavelengths. Care must be taken to assure protective eyewear in use is appropriate for the laser hazard or threat present. Laser protective visors also prevent injury to the eyes with the same limitations as described for eyewear.

b. Low energy infrared lasers can injure the eyes and/or burn the skin. Ordinary clear glass or plastic lenses or visors will protect the eye from far-infrared laser radiation such as, carbon dioxide laser radiation. Exposure to laser radiation requires line of sight; therefore, concealment, cover, or avoiding looking at a known or suspected laser threat is extremely effective for preventing injury. "DO NOT look at the light."

c. Passive protection consists of:

(1) Taking cover—get out of laser beam.

(2) Using any protective gear that is available.

(a) Protective goggles.

(b) If laser eyewear is lost or damaged, ordinary eyeglasses or sunglasses will afford a very limited amount of protection.

(c) Keep all exposed skin areas covered to prevent skin burns.

(3) Squinting can also limit the amount of laser energy that enters the eye.

NOTE

The only real protection for your eyes is the protective eyewear made for this purpose.

d. Active protection consists of using

(1) Countermeasures as taught or directed by your commander or leader.

(2) Maneuvers.

(a) Applying evasive action.

(b) Scanning battlefields with one eye or monocular optics.

(c) Minimizing use of binoculars in areas known to have lasers in use.

(d) Using hardened optical systems when available.

(3) Built-in or clip-on filters.

(4) Battlefield smoke screen.

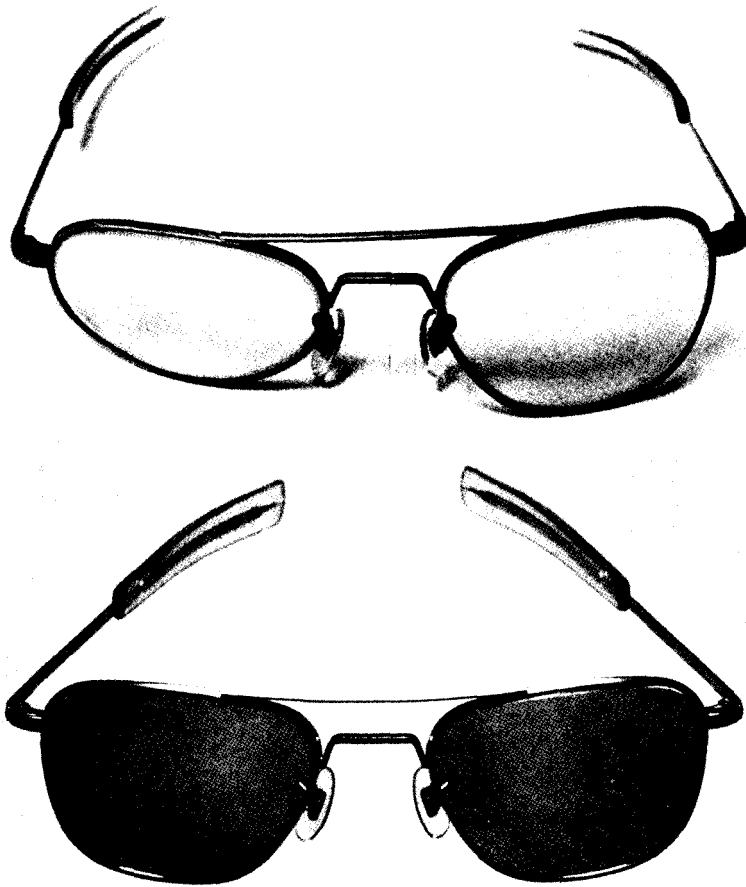


Figure 3. Protective eyewear.




Figure 3. Protective eyewear (continued).

5. Laser Radiation Dose

a. The effects produced by laser radiation are dependent on the laser radiation dose. Obviously the higher the dose, the more severe the effects. Lasers emit radiant energy in several modes:

- In a continuous wave, such as an automobile headlamp.
- In a single pulse of short duration, such as a flashbulb.
- In a repetition of short pulses, such as a disco strobe light.

The power emitted from a laser is expressed in units of energy per unit of time, referred to as the radiant power. Commonly, such power is expressed in watts, where one watt is equal to one joule (a unit of energy) per second. A one-watt laser emits 1 joule of energy in 1 second, or 2 joules of energy in 2 seconds. Some lasers, particularly laser rangefinders and target designators, emit energy in a very brief period of time (billionths of a second). A typical laser rangefinder emits 60 millijoules (60×10^{-3} joules) of energy in a 20 nanosecond (20×10^{-9} seconds) pulse. The amount of energy striking a target is referred to as the exposure dose or radiant exposure and is expressed as the amount of energy per unit of area on the target. The power per unit (irradiance) or energy per unit area (radiant exposure) is expressed in watts/cm² and joules/cm², respectively. The radiant exposure is equal to the irradiance multiplied by the exposure duration.

b. Imaging systems such as the human eye increase the irradiance or radiant exposure of collimated laser light at the image plane, such as the sensory retina for the human eye. For visible and near-infrared laser exposure of the human eye, the radiant exposure at the retina can be 100,000 times greater than that at the cornea or the skin surrounding the eye due to the focusing or imaging. Laser emission is generally well collimated; that is, the diameter of the beam increases very little with distance (low divergence). Thus the energy contained in the beam diminishes only slightly over great distances. When taken in combination, low divergence of a laser emission and the increased radiant exposure due to ocular focusing mean that low-powered lasers, such as rangefinders, pose little hazard to the skin at short ranges, but significant eye hazards at tactical ranges. Optical instruments such as binoculars or day sights increase light-collecting capabilities; therefore increase the radiant exposure at the image plane. This increases the range at which eye injuries can occur. For visible lasers, this focusing results in seeing extremely bright light at distances that exceed anticipated eye injury ranges.

c. Laser exposure dose decreases with range due to inherent beam divergence and absorption or scattering by the atmosphere. The beam diameter of a laser with a beam divergency of 1 milliradian will be about 1 meter at a range of 1 kilometer or 3 meters at a 3 kilometer range. Assuming an exit beam diameter of 2 centimeters and an emission energy of 60 millijoules, the radiant exposure at the exit aperture of the laser of 19 mj/cm^2 will be reduced to 0,007 and 0.0008 mj/cm^2 at 1 and 3 kilometers, respectively. Although the permissible exposure limit is still exceeded at 3 kilometers, the severity of the eye injury is significantly reduced. Since the exposure dose and nature of an eye injury are reduced with range, estimates on range and perception when the injury or exposure occurred are important as ancillary information to assess injury. However, future laser systems with increased emission energies, particularly those designed as optical countermeasures or antipersonnel weapons, will increase the hazard ranges.

6. Injuries

The biological effects of laser radiation on the eyes vary with the laser wavelength, pulse duration, and intensity. Visible and near-infrared laser radiation is focused by the cornea and lens onto the retina where the concentrated energy directly impacts the photoreceptor cells and supporting tissue. Ultraviolet and mid-to-far-infrared laser radiation is absorbed by the cornea and lens; alteration can occur in these tissues, but the retina will be spared.

a. Retina

(1) At the lowest levels of laser energy, temporary changes in the ability to see can be produced without permanent damage. Continuous or repetitively pulsed visible wavelength lasers can produce veiling glare while the laser is on, but disappear when the laser is turned off. The laser simply appears so bright that it is difficult to see anything else around it. At slightly higher energy, these same lasers can saturate the photoreceptor cells; resulting in after-imaging which fades with time after the laser is turned off. Only visible lasers will produce veiling glare and after-images; near-infrared lasers will not produce these effects even though the laser energy reaches the photoreceptor cells. It is important to note that these effects can also be caused by other bright light sources, such as searchlights, flares, and strobes. Further increases in laser energy levels result in irreversible retinal damage. Absorbed energy heats the retinal tissue. Heat from CW lasers causes thermal coagulation of

the photoreceptor cells and other retinal structures. The surrounding retina will be threatened by inflammatory processes and edema. These processes result in scotoma (blind spots), varying in size depending on the extent of the retinal damage. Heat is spread by thermal conduction, if exposed to repeated laser energy the area of coagulation and inflammation increases. The effect of the scotoma on visual function will vary with the size and position. For example: A small burn away from the fovea may not significantly disturb vision acuity.

(2) When the retina is exposed to pulsed laser energy, the heat cannot be carried away quickly enough by thermal conduction. The tissue is superheated and undergoes an explosive change of state, creating shock waves which mechanically disrupt tissue and spread the area of damage. If more energy is introduced, the injured area will become larger. The mechanical force produced can blow a hole through the retina and choroid, resulting in hemorrhage and may lead to severe visual loss. The blood can collect beneath the photoreceptor cell layer of the retina, disturbing its contact with the retinal pigment epitheliums resulting in retinal detachment (Figure 4). This subretinal hemorrhage can result in the death of the photoreceptor cells and a scotoma that is much larger than the thermal burn or mechanical disruption. The blood may also move into the vitreous through the disrupted retina, where it may obstruct the passage of light through the eye (Figure 5). Extensive or centrally located hemorrhage can produce a significant loss of vision. Blood in the vitreous is absorbed very slowly, but in most cases it is absorbed. The visual impairment remains as long as the blood persists; vision may improve to normal with resorption of the blood. Persistent vitreal hemorrhage may be removed by a complicated surgical technique called Vitrectomy. This procedure may also return vision to “near normal” level, if the underlying retinal/choroidal damage does not involve the fovea.

Click here

for Figure 4.

Figure 4. Subretinal hemorrhage

Click here

for Figure 5.

Figure 5. Profuse hemorrhage into the vitreous.

(3) Laser injury to the retina may damage the conducting fibers (axons) of the retina, producing a visual field defect peripheral to the site of injury. Laser damage to the retinal/choroidal areas may produce brief, severe pain. A major long-term effect of laser retinal injury is the scarring process which may degrade vision weeks or even months after the injury.

b. Cornea.

(1) Ultraviolet and low energy far-infrared radiation can injure the epithelial layer of the cornea; a condition that is painful and visually handicapping. At lower powers, this injury is primarily due to a photochemical reaction. A latency period of hours may exist between the time of exposure and the development of the corneal pathology. Minimal corneal lesions heal within a few days, but meanwhile they produce a decrement in visual performance.

(2) High energy far-infrared radiation is absorbed mainly by the cornea, producing immediate burns at all corneal layers (Figure 6). An infrared laser can produce a burn resulting in immediate visual incapacitation and may lead to permanent cornea scarring. Very high energy can perforate the cornea; this perforation may lead to loss of the eye.

c. Skin Burns. The threshold for skin burns is similar to that of the cornea for ultraviolet and far-infrared wavelengths. For visible and near-infrared wavelengths, the skin's threshold is much higher than that for the retina, since there is no focusing power as will occur in the eye. However, minimal lesion to the cornea is much more debilitating than a minimal skin burn.

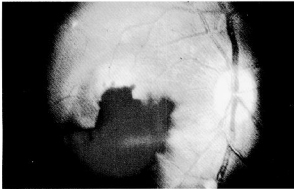
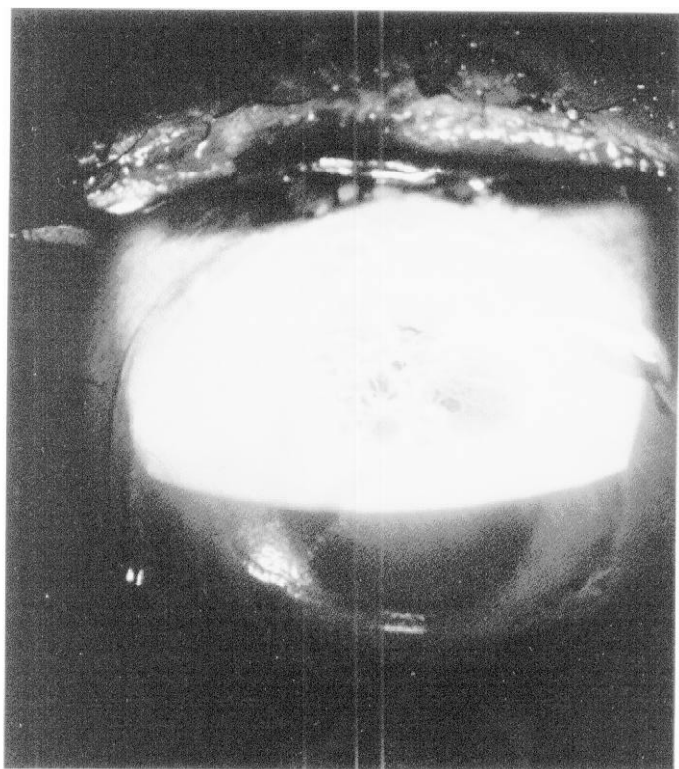
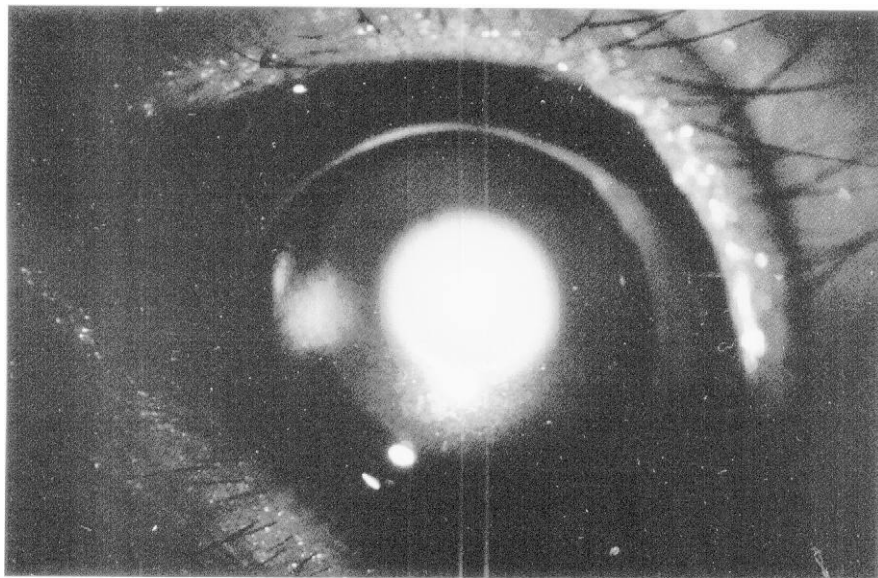


Figure 5. Profuse hemorrhage into the vitreous.



7. Symptoms

The main symptom of laser injury is reduction in visual acuity; another symptom may be pain. Medical personnel should suspect laser exposure when soldiers report seeing bright flashes of light; experiencing eye discomfort and poor vision; and feeling unexplained heat. Obvious lesions such as corneal burns, retinal injury and hemorrhage, and skin burns make the diagnosis more certain. Conceivably, one may confuse the use of invisible lasers with chemical agents which also irritate the eyes and skin (see FM 8-285 for signs and symptoms of chemical agent injuries). Spontaneous fires and unexplained damage to optical instruments are additional evidence that laser devices/weapons are being employed.

NOTE

Report any suspected laser injury immediately to medical care providers and tactical commanders.

8. Physical Findings

a Temporary (Short-Term). Burns of the skin and cornea indicate that an infrared or ultraviolet laser has been used. Significant retinal hemorrhage probably means that a pulsed laser in the visible or near-infrared portion of the spectrum has been employed. Isolated retinal burns without significant hemorrhage probably indicate the use of a visible laser in the continuous wave mode (Figure 7). At lower exposure levels, the visible laser can impair visual function for as long as the laser source is visible. When the laser exposure terminates, vision will recover to normal without observable changes in the structure of the eye.

C l i c k h e r e

f o r F i g u r e 7 .

Figure 7. Multiple small laser burns with minimal hemorrhage.

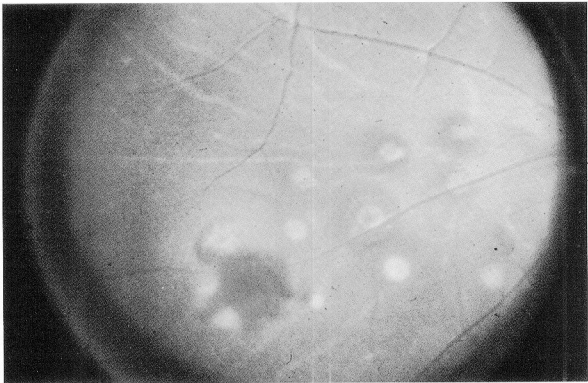


Figure 7. Multiple small laser burns with minimal hemorrhage.

b. Permanent (Long-Term). In these cases there are alterations of ocular tissue; they include--

- (1) Circumscribed lesions of the retina.
- (2) Lesions of the retina with bleeding into the vitreous.
- (3) Severe corneal burns.

9. Evaluation of Suspected Laser Injuries

Evaluation of possible laser injuries requires a search for specific findings on physical examination. The combat lifesaver and combat medic must determine quickly if the affected soldier is fit to return to duty or if he should be referred to the battalion aid station for further evaluation and/or treatment. Appendix B provides a simple matrix for use by the combat lifesaver and combat medic in performing their evaluation. Table 1 provides a matrix for use by other medical providers in evaluating and treating laser injuries prior to their arrival at a medical treatment facility where definitive care can be provided by an ophthalmologist, if required.

10. Treatment

a. Burns. Far-infrared laser burns of the cornea and skin are treated similarly to other types of thermal burns. If not perforated, apply antibiotic ointment to the eye then patch. The patient should also receive systemic broad spectrum antibiotics coverage and systemic analgesic. There is very little likelihood of an isolated eye burn; the eyelids, skin of the face, and other parts of the body will be affected and should be treated (see FM 8-230 for treatment of burns).

b. Retinal Injuries. Currently, there is no proven treatment of retinal laser lesions except for surgical intervention (vitrectomy) for severe vitreous hemorrhage. A patient diagnosed with a laser retinal injury is evacuated to a hospital where he can be examined by an ophthalmologist. A vitrectomy consists of removing the vitreous of the eye and the hemorrhage. This procedure can only be performed in a hospital by specially trained ophthalmologists. The decision to perform a vitrectomy is made only by a specially trained ophthalmologist.

NOTE

For laser burns to the cornea, only the injured eye is patched, after applying eye ointment. Do not patch both eyes unless both have been burned. Retinal burns do not require eye patches. They only make the patient more disabled by taking away all of his vision; thus, further emphasizing his injury.

Table 1. Symptoms, Signs, Diagnosis, and Treatment of Laser-Induced Injuries

Symptoms (Reported by patient)	Signs (Findings on examination)	Diagnosis (and likely laser etiology)	Treatment and management
Skin and Anterior Eye Injuries			
Reduction in vision. Pain in eye, eyes tender. Red or warm face or skin.	White or hazy cornea. Conjunctival inflammation. Facial or skin erythema.	Mid-moderate corneal and/or skin burn. (Infrared laser, intermediate dose.)	If eye perforation is not suspected, apply topical antibiotics (ointment). Patch.
Profound loss of vision. Severe pain in eyes. Burning sensation of face or skin.	Corneal ulceration or loss of corneal tissue. Perforation of globe. Skin burn.	Severe corneal and/or skin burn. (Infrared laser, high dose.)	Systemic antibiotics and pain medication.* Needs physician/PA** evaluation. Evacuate as appropriate.
Retinal Injuries			
Temporary loss of vision. Bright light experience. No pain.	External exam: normal. Internal exam: normal.	Glare, dazzle, or flash-blindness. (Low dose laser.)	None. Return to duty.
No or slight visual impairment. Dark spot in field of vision.	External exam: normal. Internal exam: Non-foveal retinal lesion(s).	Small non-foveal, retinal burn with no or minimal hemorrhage (visible or near-infrared laser, low to medium dose).	None. Return to duty if able to function.
Vision impaired. Large dark spot at or near center of vision.	External exam: normal. Internal exam: foveal retinal lesion(s).	Peri-foveal retinal burn, and/or hemorrhage (visible or near-infrared laser, medium dose).	Evacuate. Needs physician/PA evaluation.
Severe visual impairment. Large dark spot at or near center of vision. Large floating objects in eye. May see blood.	External exam: normal. Internal exam: foveal retinal lesion(s) which may be obscured by vitreous hemorrhage.	Foveal retinal burn, with vitreous or subretinal hemorrhage (visible or near-infrared laser, high dose).	Evacuate. Needs physician/PA evaluation.*

*Oral aspirin or intramuscular analgesics may be used as needed. Topical anesthetics such as tetracaine or proparacaine are never prescribed, but may be used on a *one-time basis only* to aid examination. Repeated use of topical anesthetics may predispose to further corneal injury.

**The optometrist at the MSMC may be consulted on questionable cases.

11. Evacuation Criteria

The capability for medical evacuation, the intensity of the battle, and the patient will determine if he will be evacuated or will remain engaged. A visual function assessment, as well

as other findings such as hemorrhage, will be used to determine the soldiers' duty status. The combat lifesaver and combat medic must consider the soldier's need for evaluation by a physician/PA (to include an ophthalmoscopic examination). From this information, one can determine the need for evacuation of the patient. Ground ambulance is the preferred method of evacuation; the lack of urgency for treatment does not justify aeromedical evacuation. See FM 8-10-6 for additional information on evacuation.

12. Stress

a. The hazards of the current laser rangefinders and target designators (from flash effects to blindness) provide the potential for substantial psychological effects on soldiers. It is inevitable that at least some soldiers will suffer laser injuries to their eyes. The reaction of the injured soldiers and their buddies will depend on:

(1) Their response to the stress of a new, silent, futuristic weapon on the battlefield.

(2) Their training and knowledge about laser weapons.

(3) The treatment they receive after being wounded. Laser injuries may be especially stressful; vision is one of our primary means of relating to the world about us; and the fact or prospect of being deprived of vision will be a source of fear. The soldier's buddy who has been accustomed to seeing external wounds of combat may have some reluctance to accept a disabling injury without outward evidence. Yet looking at the world through his own blood as a result of laser-induced retinal hemorrhage may cause panic in the afflicted soldier and terror in his buddies.

b. Several aspects of the laser threat increase mental stress relative to that produced by other weapons. The fact that lasers travel at the speed of light along line-of-sight gives a new urgency to the saying "If you can be seen, you can be hit." This may produce the types of psychological stress reactions and inhibitions of combat initiative which have been described in response to sniper fire. However, unlike the sniper's bullet, most lasers produce serious injury only to the extent that the target is looking at the laser source and/or through optical equipment. Because the danger is so specific, soldiers may be especially inhibited from performing critical surveillance, target acquisition and aiming tasks. This is especially likely if they have just seen their fellow soldier suffer the effects of laser while performing those tasks.

c. Laser training must provide the soldier with the knowledge to protect himself. He must be aware that protective equipment for certain laser frequencies is available; additional protection is anticipated from ongoing research. Understanding lasers requires a certain amount of technical information. As lasers become more widespread on the battlefield, the soldier may become accustomed to their use. But the soldiers' fear of laser injury may increase as laser injuries increase. Flashes of blinking lights will be commonplace on the battlefield, and often must be looked at carefully to determine if they should be engaged as targets. Fear of total blindness is a very strong fear. In the imagination of some soldiers whose careers, activities, and self-image depend heavily on vision, blindness may rank high as a crippling wound which makes a person helpless and an object of pity.

d. Treatment following a laser injury is extremely important. Calm, professional treatment at each echelon of medical care is mandatory, including reassurance that the injury is not life-threatening and that chances for some, if not total, recovery is good. The potential psychological effects of lasers could be enormous. It is imperative that secondary gain be minimized by prompt return to duty of those individuals with temporary flash-blindness or noncritical (non-foveal) burns of the retina without hemorrhage. If an error is to be made, it should be on the side of return to duty of questionable injuries. Medical management of stress reactions for patients suffering from real or imagined laser injuries is like stress management of other injuries. Repeat the reassurance that symptoms will improve with rest, nutrition, hygiene, and the expectancy of an early return to the soldier's unit. For specific combat stress control procedures, see FM 8-51.

e. Strategies need to be developed to reduce the psychological impact on soldiers by the anticipated increase in lasers on the modern battlefield. As with the use of individual or collective chemical protective equipment, the use of protective eyewear is not a simple solution which guarantees 100 percent safety. The leader and the individual soldier must be trained to accept necessary risk to accomplish the mission in accordance with METT-T, taking into account the risk of laser injury from both enemy and friendly lasers.